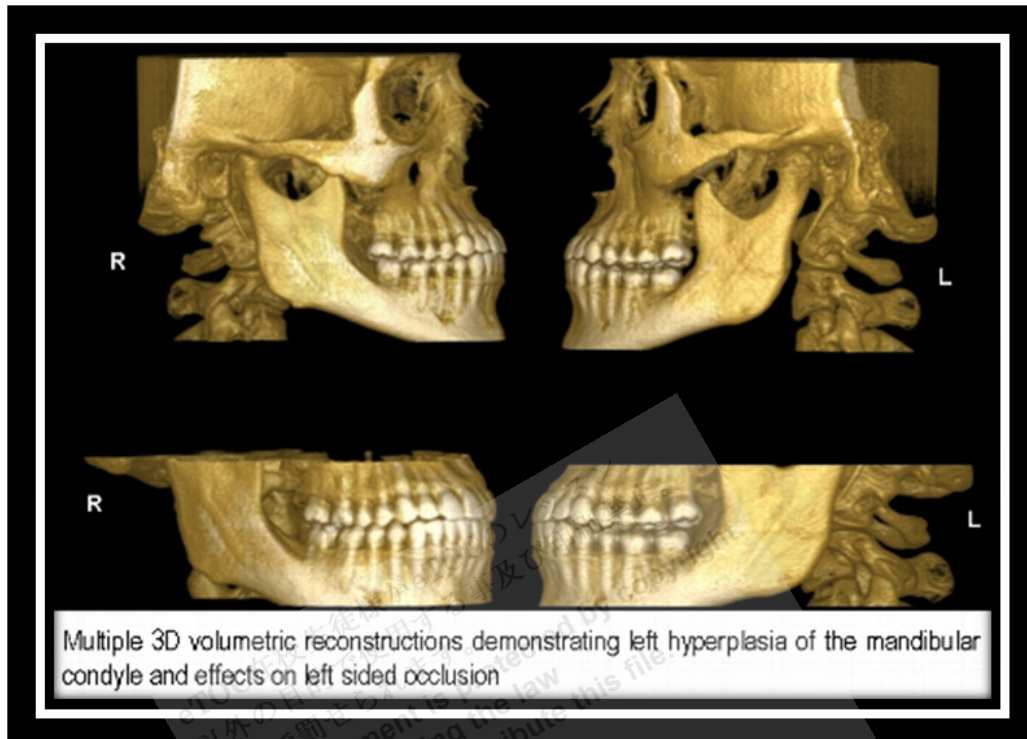


Condylar Hyperplasia



http://www.dmfua.com/resources/wsb_482x332_Slide8.PNG

Condylar hyperplasia is a disorder of unknown etiology characterized by persistent or accelerated growth of the condyle when growth should be slowing or ended. Growth eventually stops without treatment.

Slowly progressive unilateral enlargement of the head and neck of the condyle causes **crossbite malocclusion**, **facial asymmetry**, and shifting of the midpoint of the chin to the unaffected side. The patient may appear **prognathic**. The lower border of the mandible is often convex on the affected side. **Chondroma** and **osteochondroma** may cause similar symptoms and signs, but they grow more rapidly and may cause even greater **asymmetric condylar enlargement**.

Diagnosis

- Plain x-rays
- Usually CT

On x-ray, the **temporomandibular joint** may appear normal, or the condyle may be proportionally enlarged and the **mandibular neck** elongated. CT is

usually done to determine whether bone growth is generalized, which confirms the diagnosis, or localized to part of the condylar head. If growth is localized, a biopsy may be necessary to distinguish between tumor and **hyperplasia**.

Treatment

- During active growth, usually **condylectomy**
- After growth cessation, **orthodontics** or surgical mandibular repositioning

Treatment usually includes **condylectomy** during the period of active growth. If growth has stopped, orthodontics and surgical **mandibular repositioning** are indicated. If the height of the **mandibular body** is greatly increased, facial symmetry can be further improved by reducing the inferior border.

Reference: <http://www.merckmanuals.com>

eTOC在校生徒様がeTOCのレッスンを
以外目的で使用すること及び印刷禁止。
法律で罰せられます。
This document is protected by copyright.
You are breaking the law
if you copy or distribute this file.

eTOC
English Teachers On Call